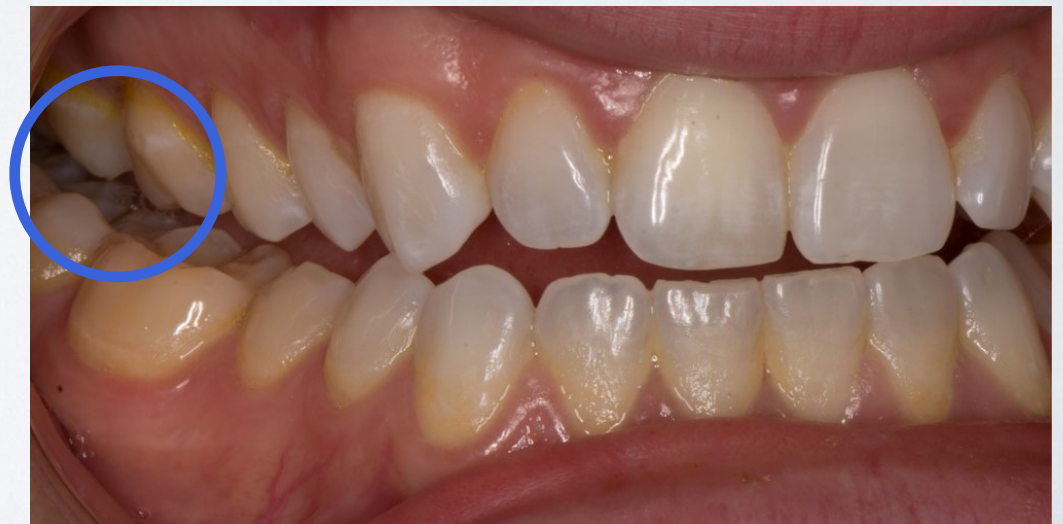
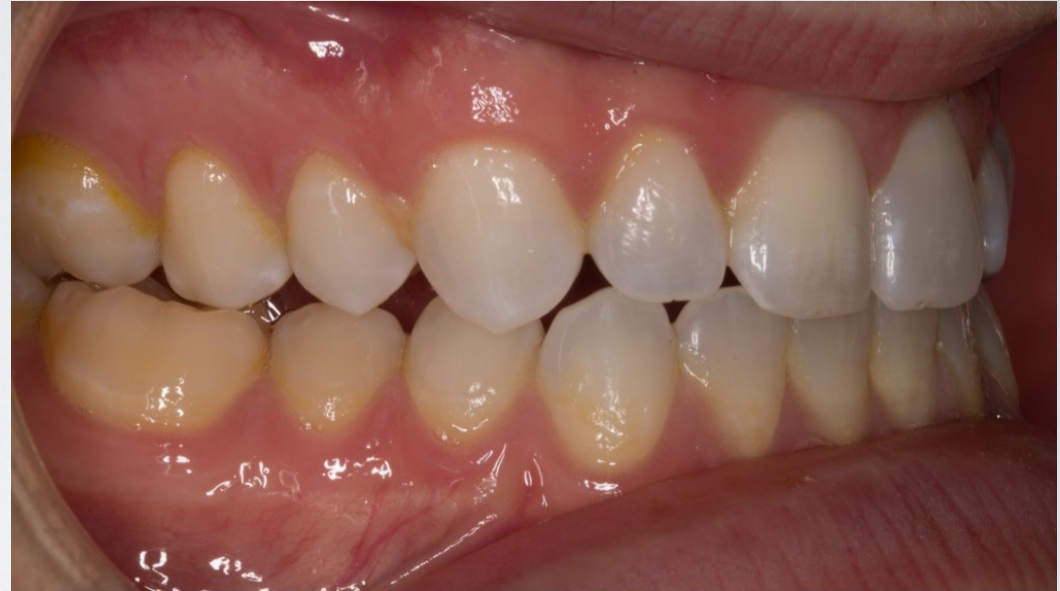
ALTERNATE OCCLUSAL SCHEMES

The same basic concepts need to be applied to all occlusal schemes. Some challenges include missing teeth, transposed teeth, crossbites, and anterior open bites.

POSTERIOR CROSSBITES

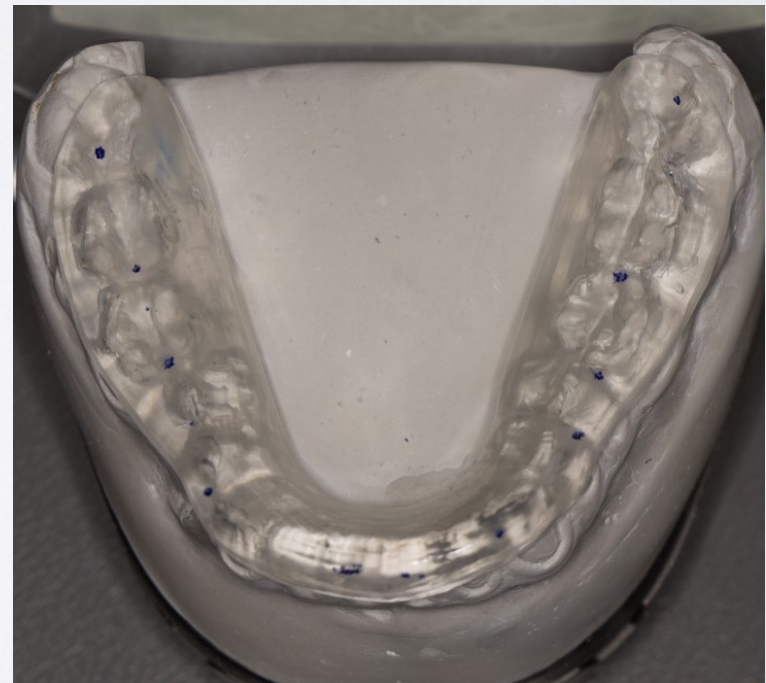
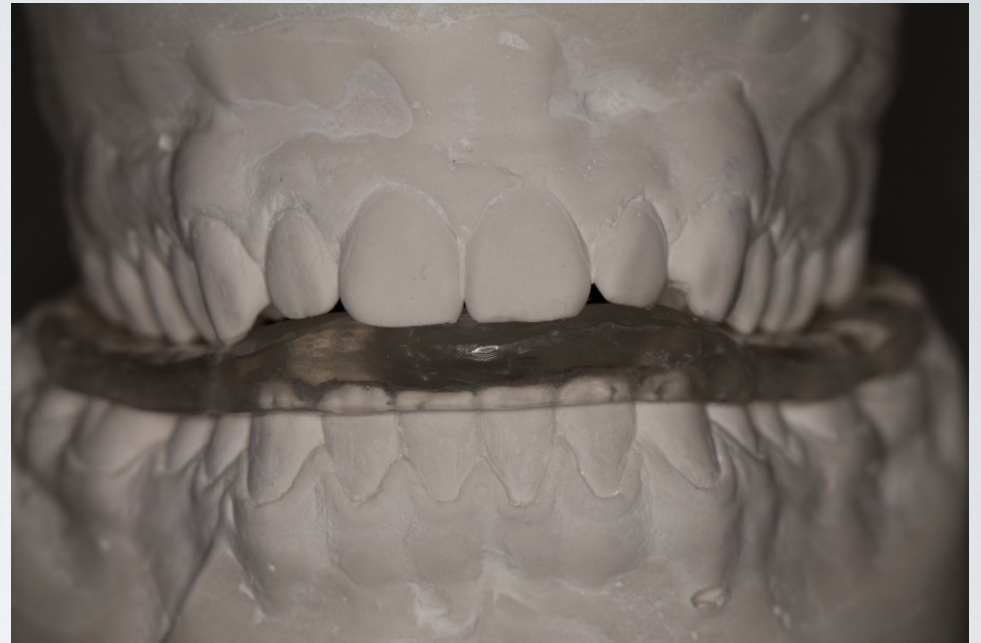A typical occlusal interference in a crossbite is steep posterior inclines the prevent canine guidance.



RIGHT EXCURSION WITH INTERFERENCES

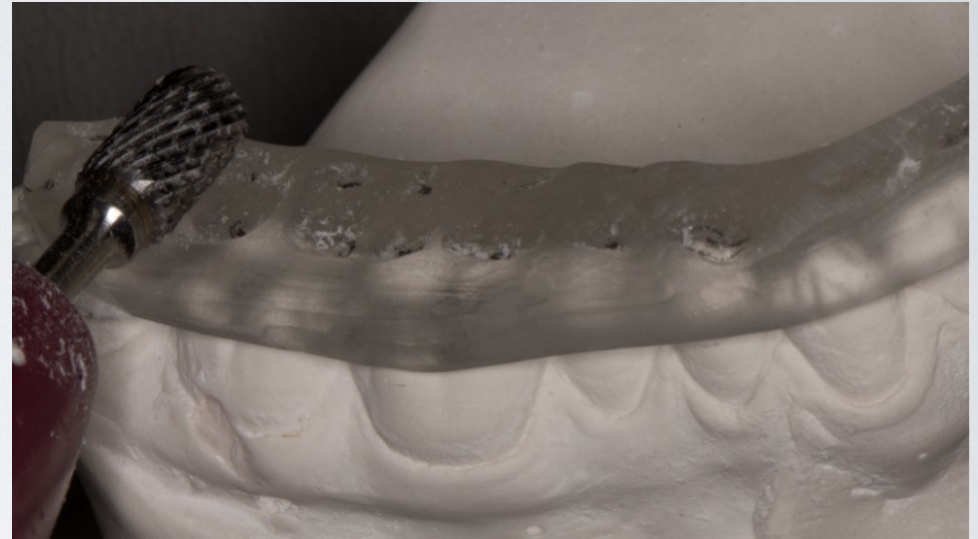
POSTERIOR CROSSBITES

- The goals of a splint for this bite are the same: smooth immediate anterior canine guidance and solid posterior contacts.
- Start with material greater than 2mm in the anterior to ensure enough thickness for the posterior.



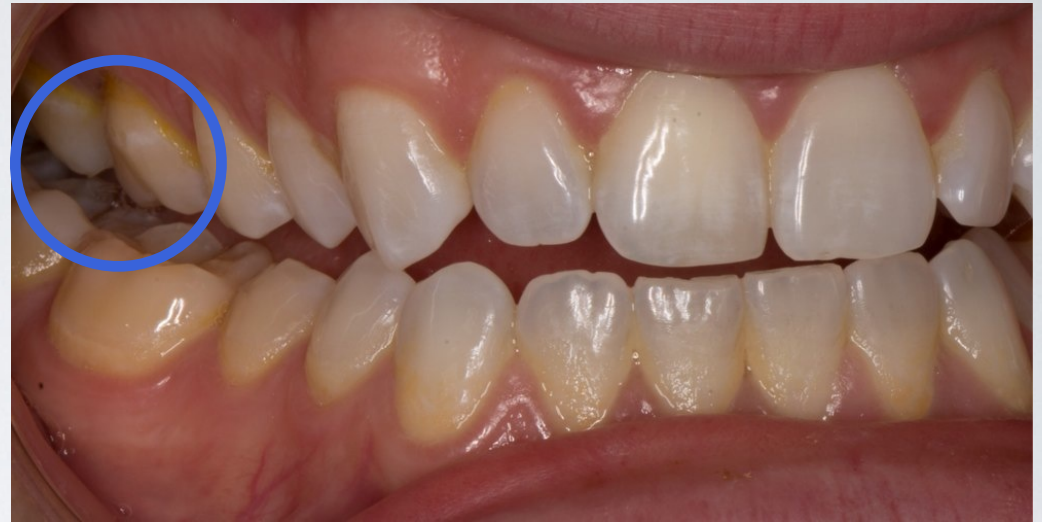POSTERIOR CROSSBITES

- The technique of stamping upper cusps into doughy acrylic develops indentations of upper buccal and lingual cusps - if possible, view the upper lingual cusp as the preferred cusp to achieve the desired effect on the maxilla.
- Accept using a buccal upper cusp as the primary receiving cusp for the transitional tooth “crossing the bite” (typically the premolar).

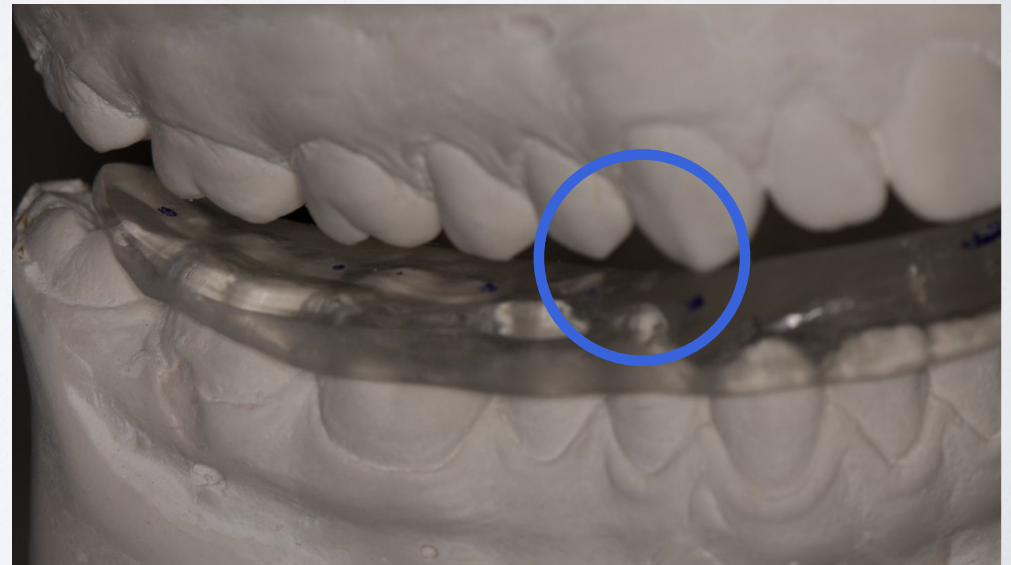

POSTERIOR CROSSBITES

Confirm the splint accomplishes the goals before taking it to the mouth: shallow canine guidance with no interference by the molars, and balanced posterior contacts.



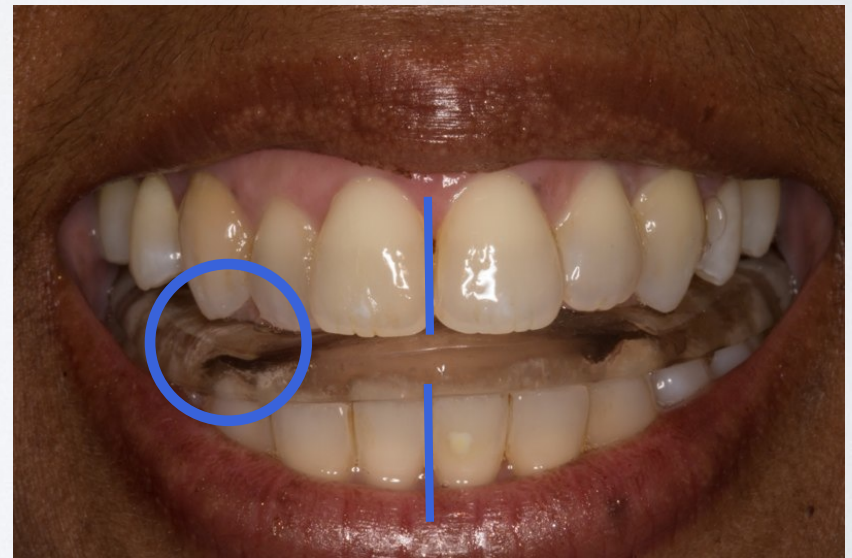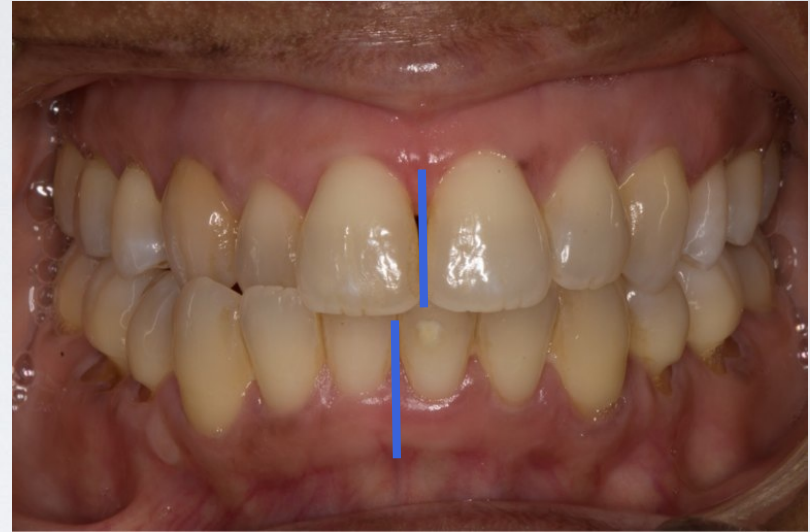RIGHT EXCURSION GUIDED BY MOLAR



CANINE GUIDANCE WITH MOLAR CLEARANCE

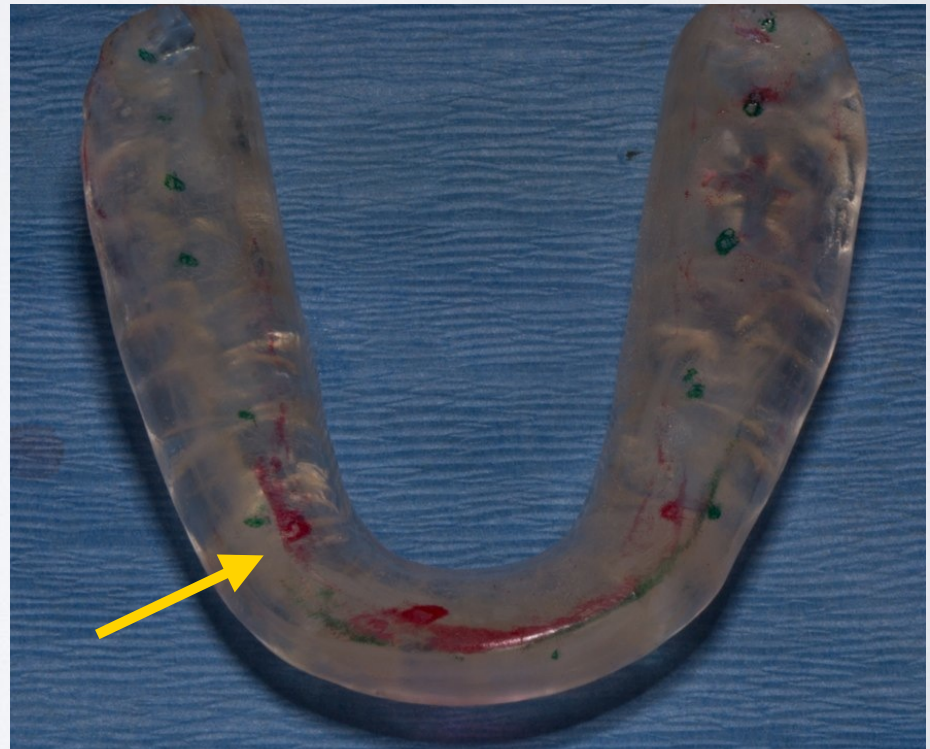
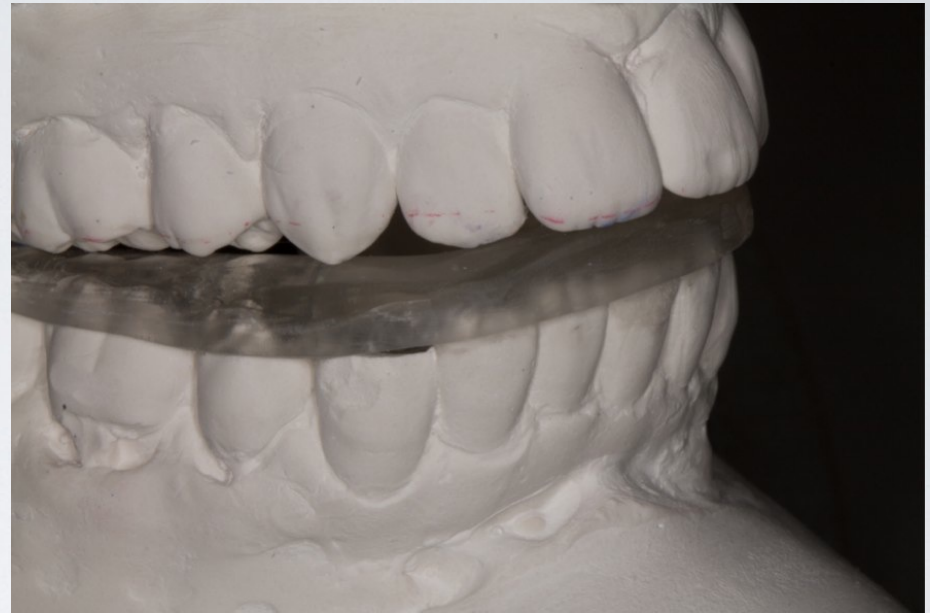ANTERIOR CROSSBITES

Unilateral crossbite in the anterior segment frequently represents an exaggerated midline shift. Using a bite splint deprograms the ingrains that posture the jaw. In addition to revealing a less distorted midline, splint therapy commonly results in a more cusp-to-cusp tip orientation at the canine.



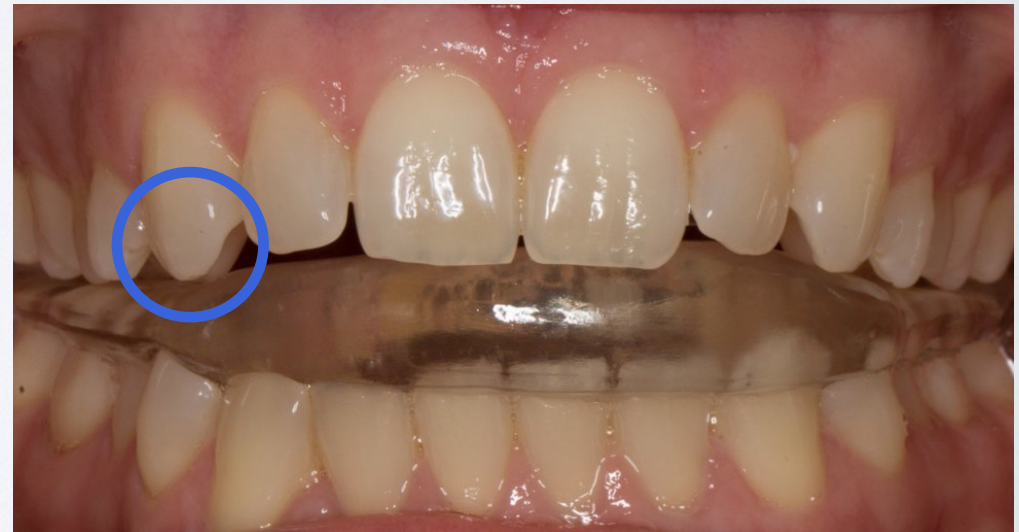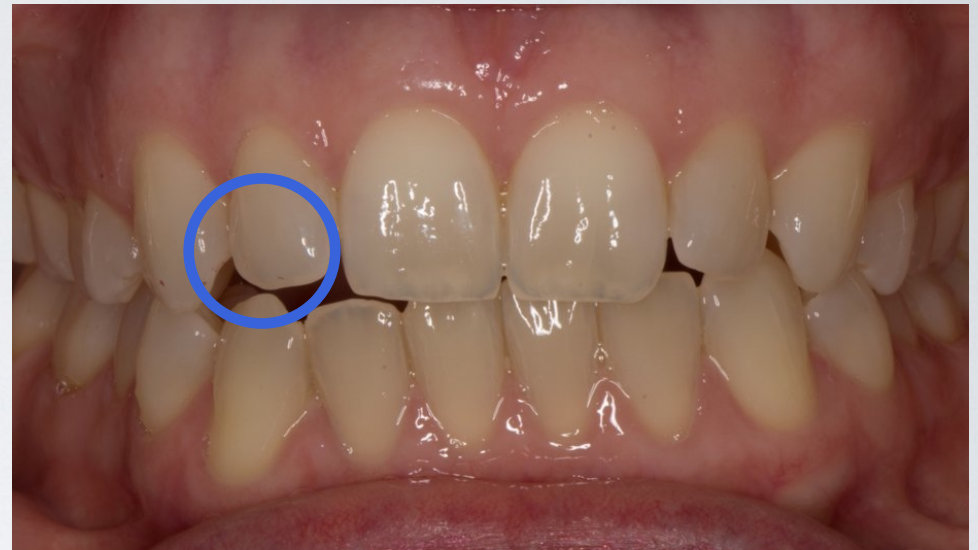ANTERIOR CROSSBITES

After reducing influence of jaw position ingrams, the canine can be engaged in lateral excursion function like normal. Even here it is ideal to have lingual surface of canine engage prior to cusp tip passing over top of splint - arrow on lower picture shows the bare minimum of lateral pressure the canine needs to serve as a proprioceptive reference.



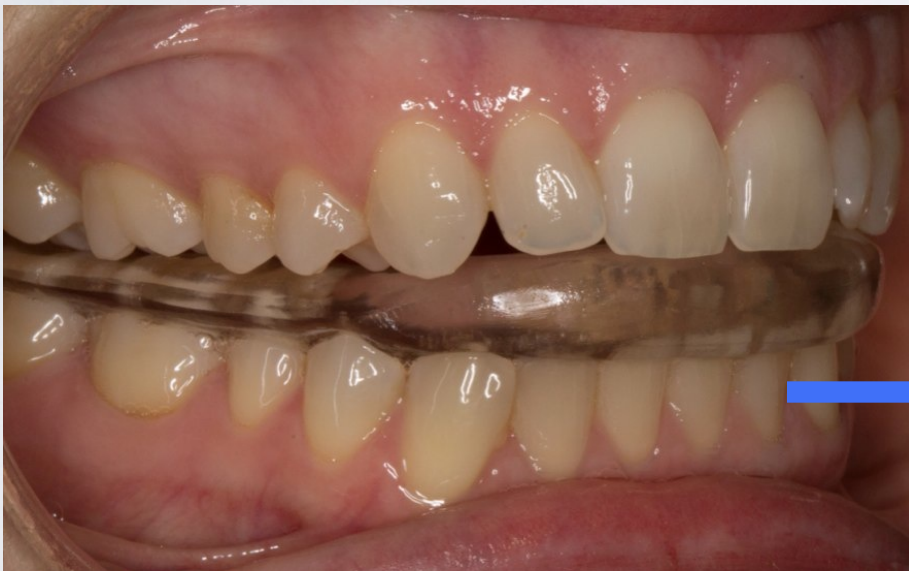ANTERIOR BITE DISTORTIONS

Even a canine out of position can receive sensory input from a food bolus. Design a splint to engage this tooth with “kissing” pressure during lateral excursions.

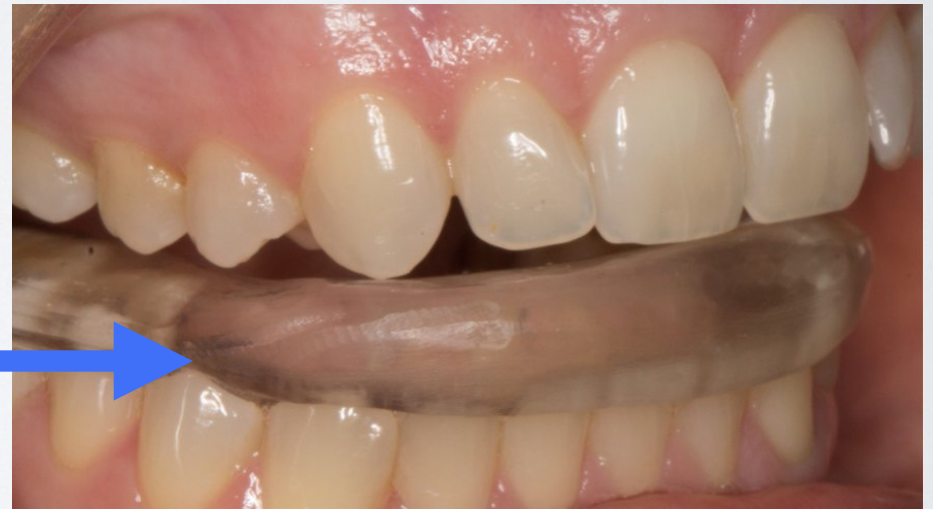

ANTERIOR BITE DISTORTIONS

This patient has not felt pressure on the canine previously. The key to this vibration being acceptable is to make it a short, smooth, shallow stroke that is immediately transferred to the central incisor.



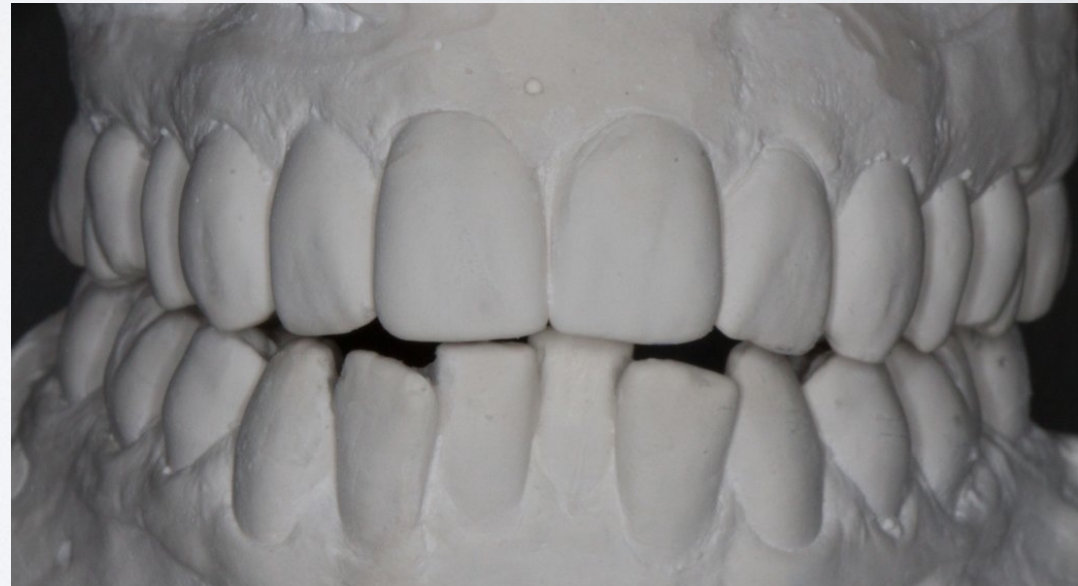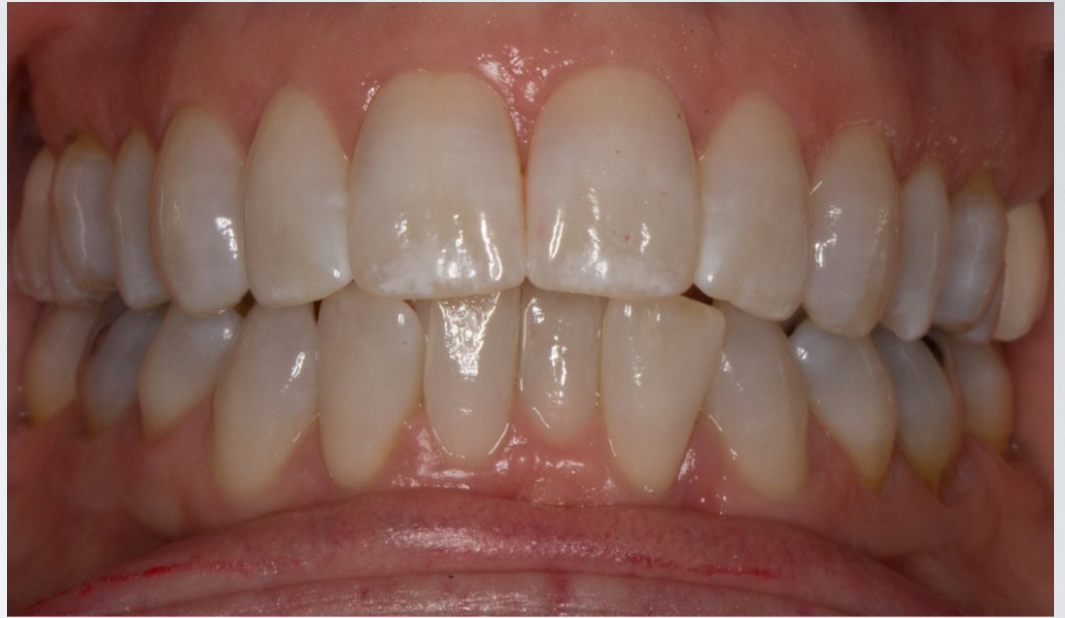**ENGAGING LINGUAL SURFACE OF
UPPER CANINE LIGHTLY**



**RIGHT EXCURSION IS CANINE-GUIDED
WITH QUICK CROSS-OVER**

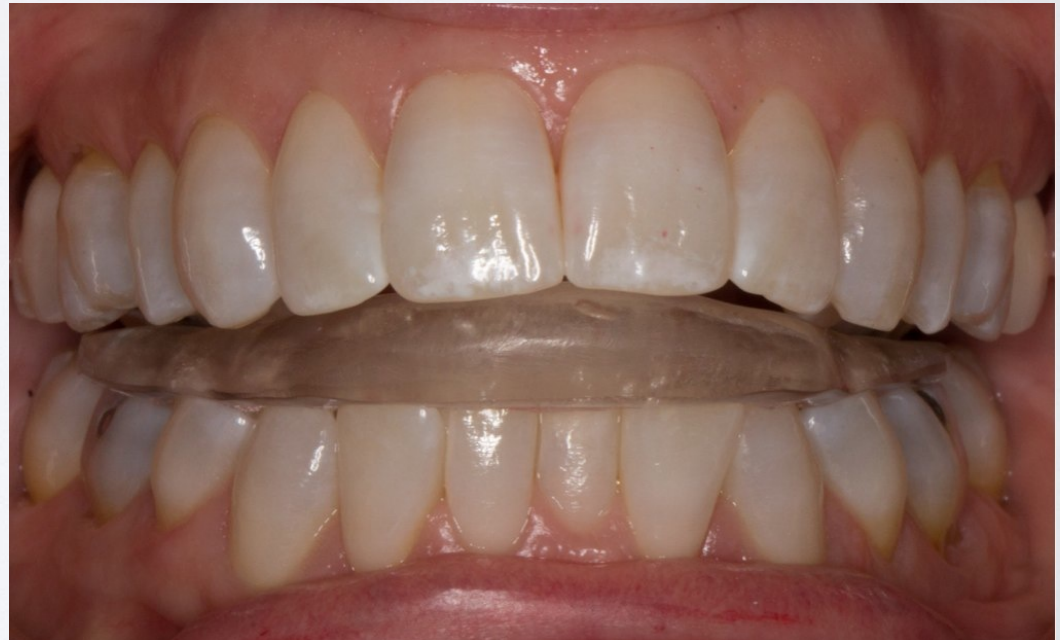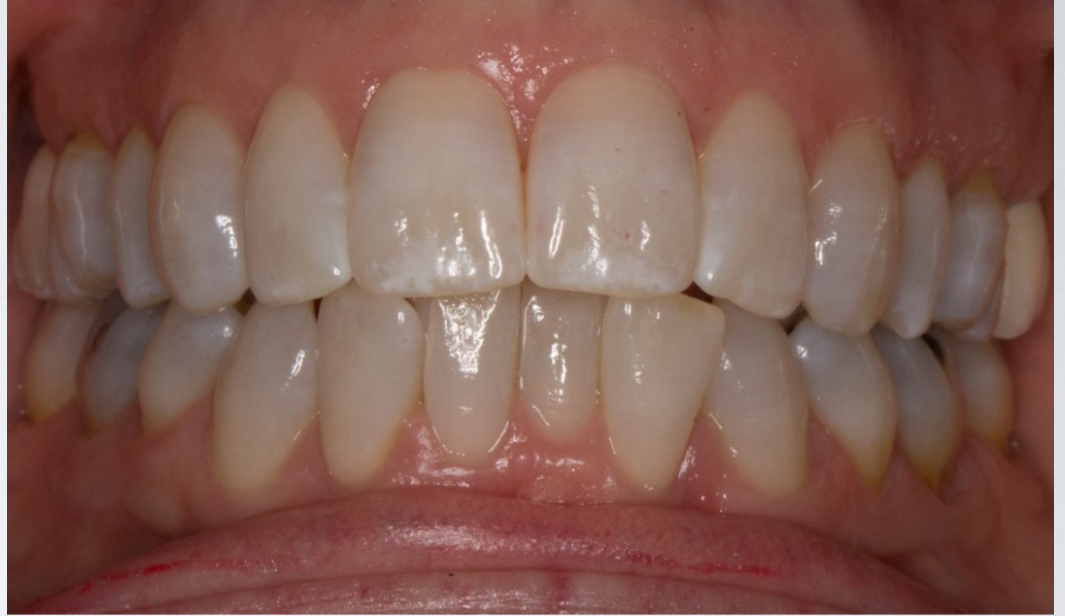ANTERIOR OPEN-BITE OCCLUSION

Patients with bilaterally displaced TMJ disks will frequently have masked the severity of the anterior open bite distortion that occurs by repositioning the mandible as well as increasing forward head position and taking OA extension to a maximum. Accurately mounted study models taken **after** the cervical curvature has been supported can reveal that discrepancy.



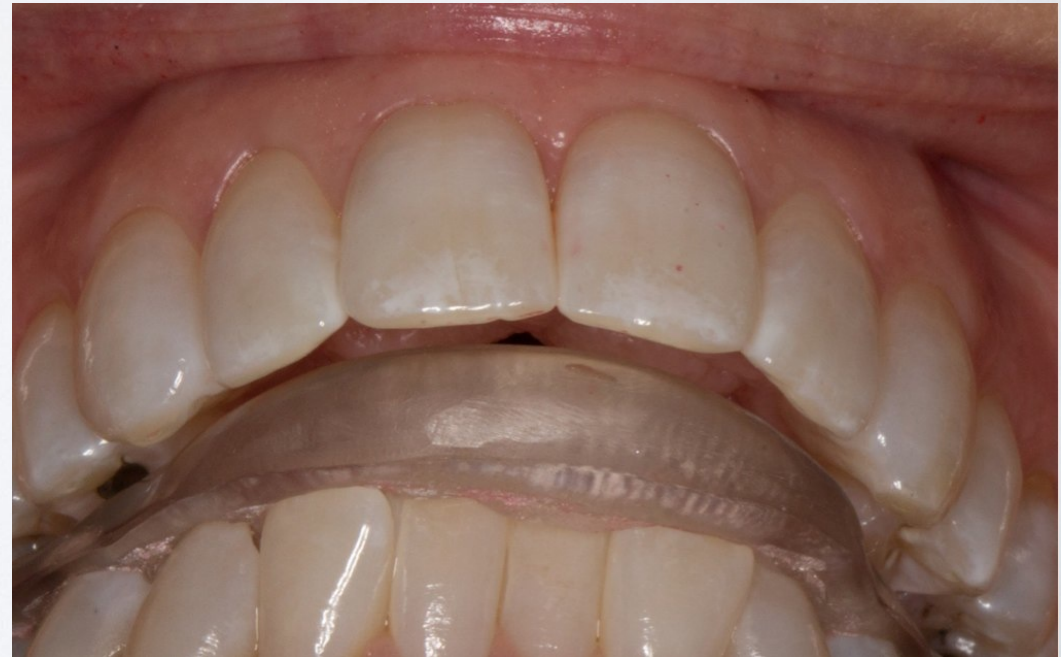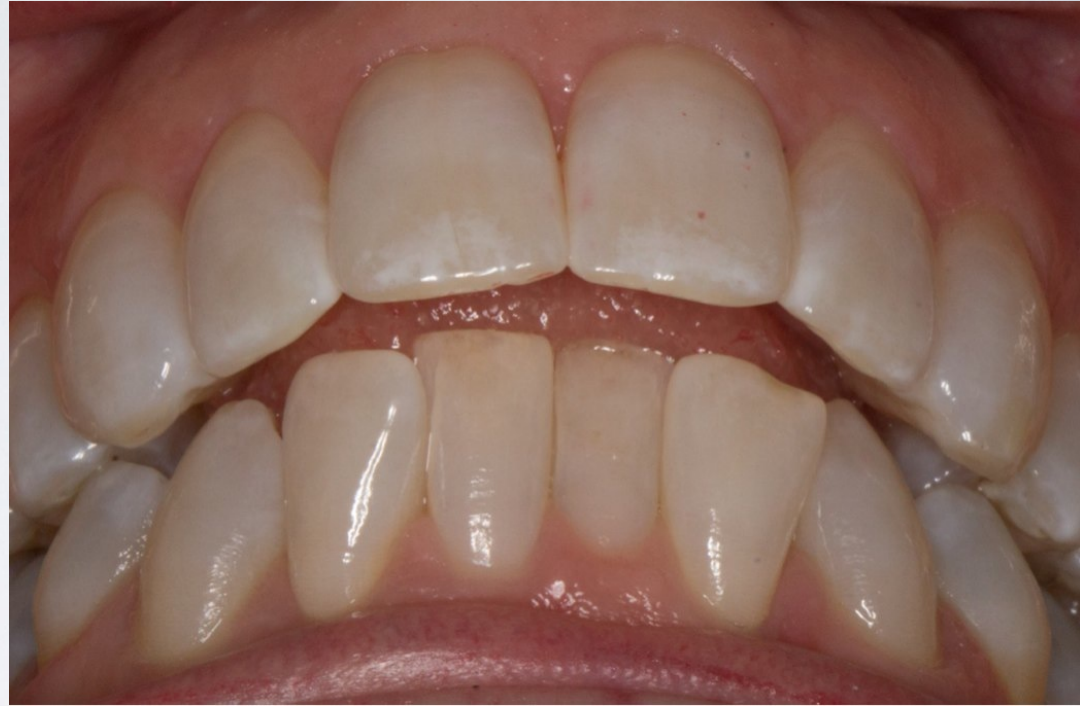ANTERIOR OPEN-BITE OCCLUSION

Following the same design principles as other cases yields solid posterior stops bilaterally and smooth canine guidance - however, canine guidance does not need to be immediate to provide effective canine proprioceptive sensing. *(there may be a “long centric” slide by the cusp tip of a posterior tooth along the flat surface of the splint.)*



ANTERIOR OPEN-BITE OCCLUSION

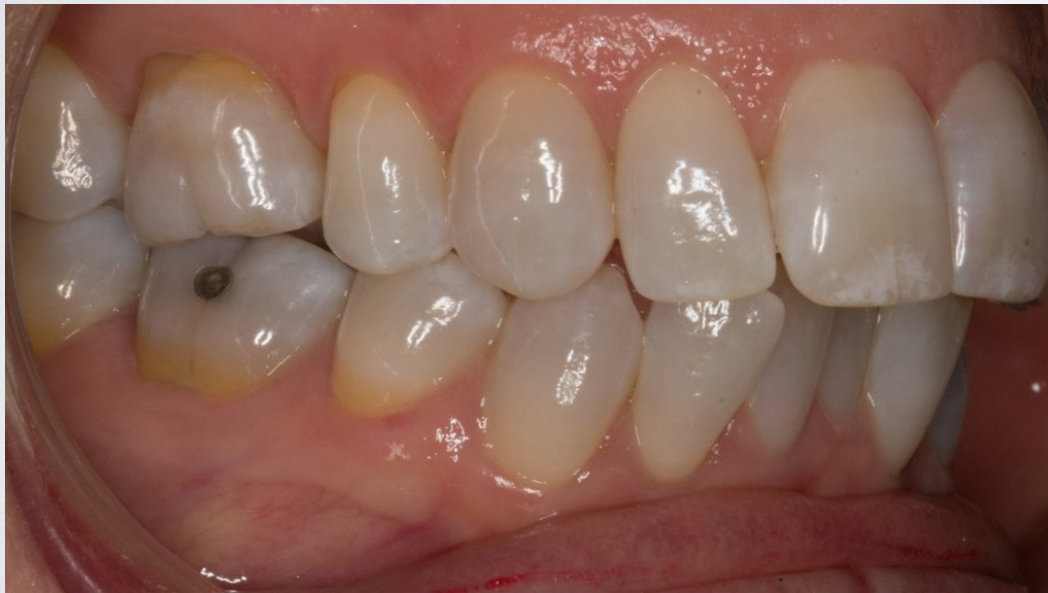From this angle, see that this splint has a slight open contact at the canine, and increasingly open contact at the incisors. This design mimics the natural dentition, but creates a more closely approximated relationship between the upper teeth and splint, than that which exists between upper and lower teeth.



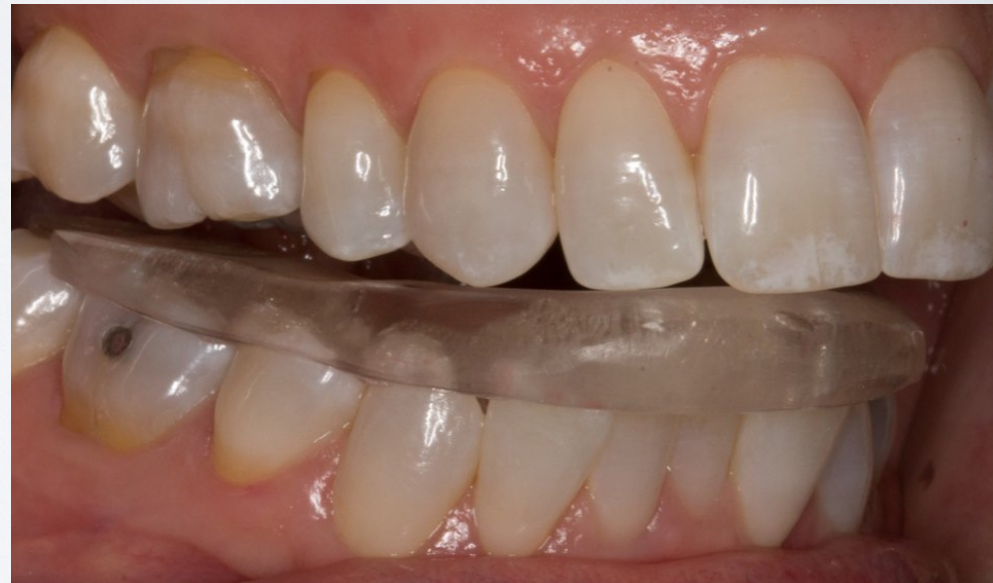ANTERIOR OPEN-BITE OCCLUSION

Releasing the dentally-locked in pattern in lateral excursions is limited until protrusive jaw movements are smooth.

Protrusion of the jaw on a well-supported neck reduces the extreme extension of OA joints.



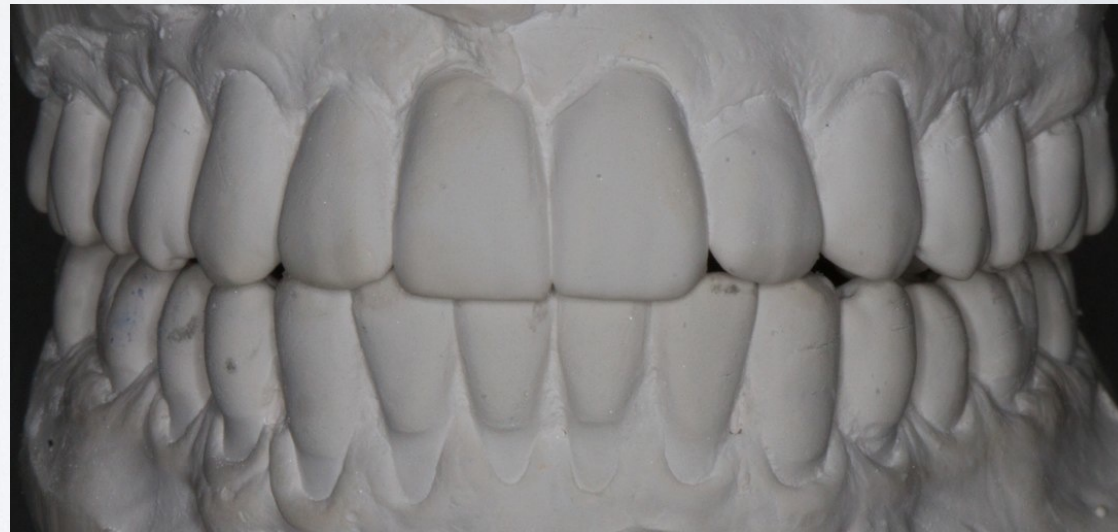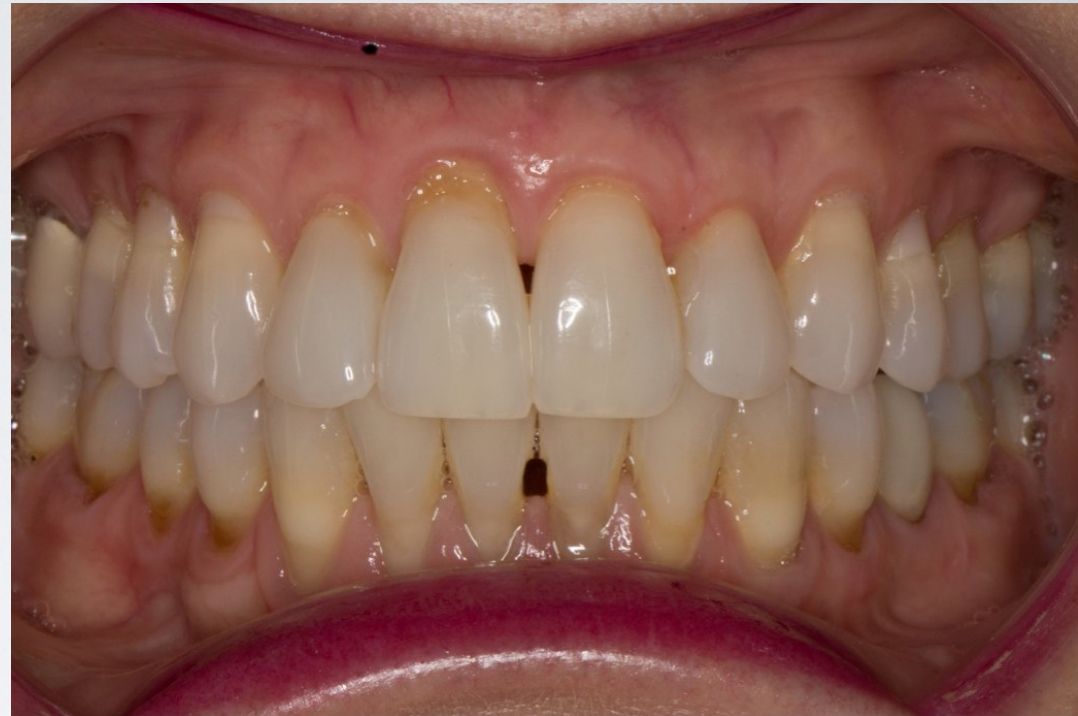**PATIENT ATTEMPTING RIGHT
EXCURSION; LOCKED IN AND
UNABLE TO SLIDE JAW**



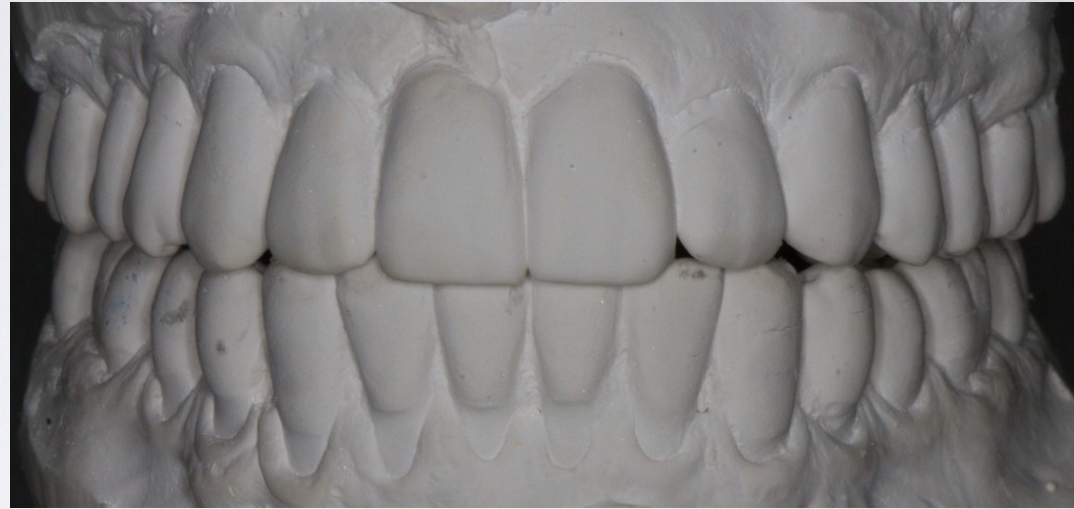**PATIENT NOW FREE
TO SLIDE JAW
WITHOUT DIFFICULTY**

POSTERIOR OPEN-BITE OCCLUSION

Patients managing an airway problem with night-time use of a mandibular advancement device may develop a posterior open bite. Attempting to reapproximate the posterior teeth in this occlusal distortion involves mandible retrusion and OA flexion, thus reversing the natural lordosis of the neck. Accurately mounted study models taken **after** the cervical curvature has been supported can reveal that discrepancy.

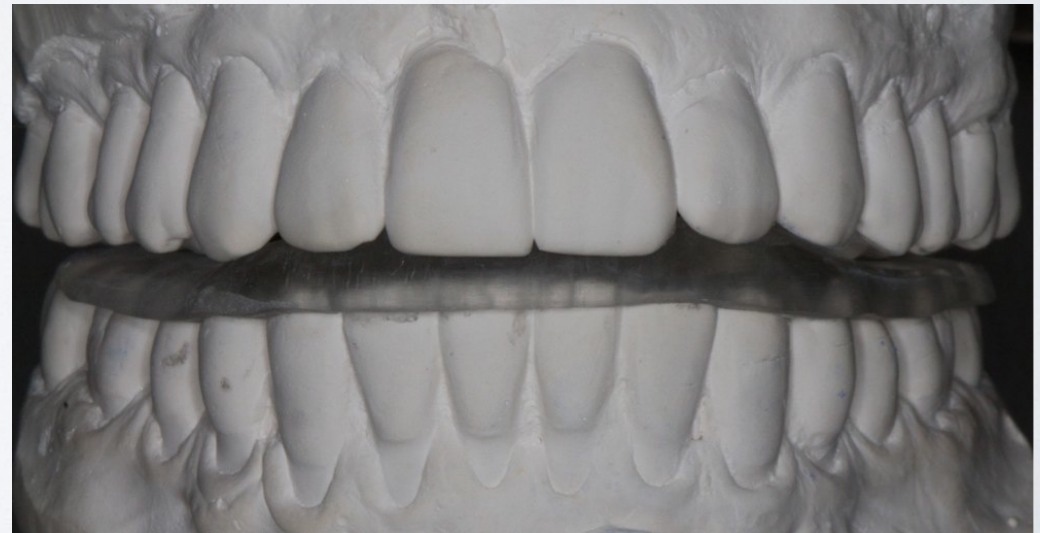

POSTERIOR OPEN-BITE OCCLUSION



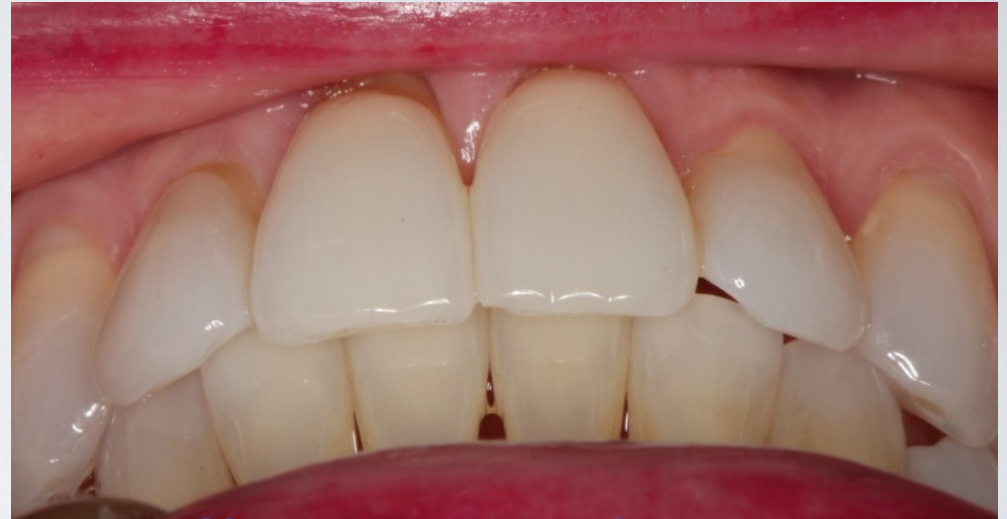Identical principles of splint design are employed as in other cases:

- Solid posterior stops
- Light anterior occlusion
- Shallow anterior guidance
- Smooth crossover

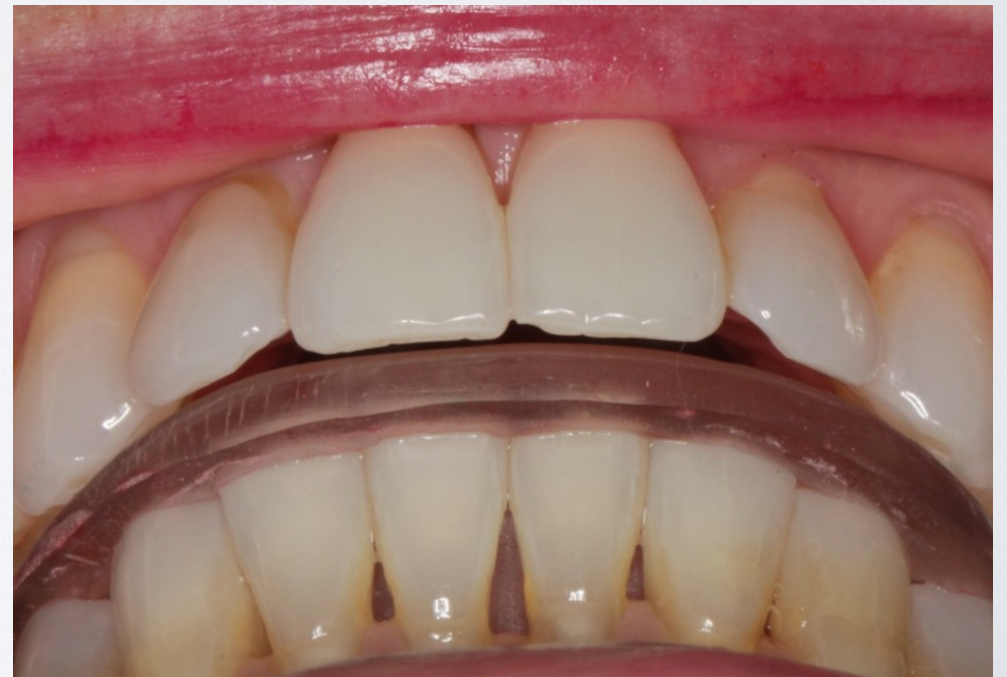

POSTERIOR OPEN-BITE OCCLUSION

Patients with posterior open bites experience repetitive occlusal trauma to the anterior teeth. Designing the splint to provide a little clearance to these teeth on full closure will allow the PDL to recover from the trauma.



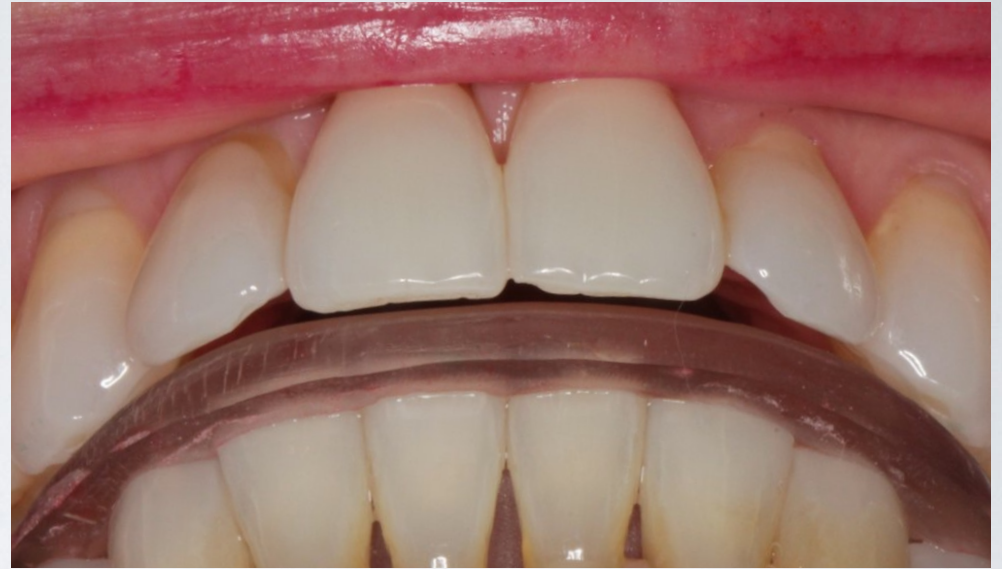**Heavy anterior tooth contact
prior to splint insertion**



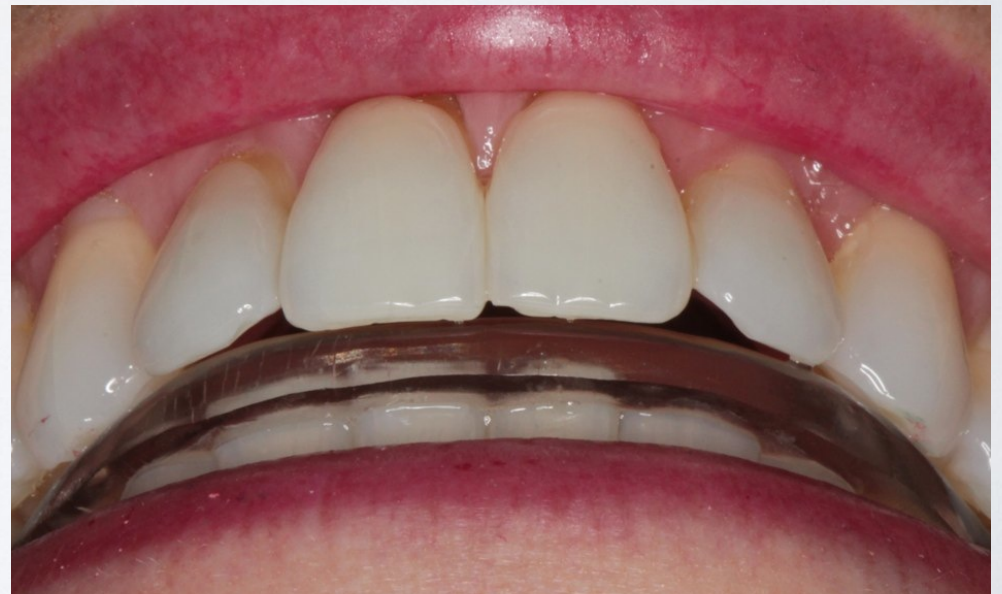**Freedom of anterior tooth contact at
splint delivery appointment**

POSTERIOR OPEN-BITE OCCLUSION

As the PDL of the front teeth tightens, the upper incisors will yet again make an impact against the leading edge of the splint. Several appointments may be necessary to relieve the anterior tooth contact pressure over and over. As the lower jaw has more freedom to come forward, the cranium has the freedom to rotate posteriorly on the Atlas.



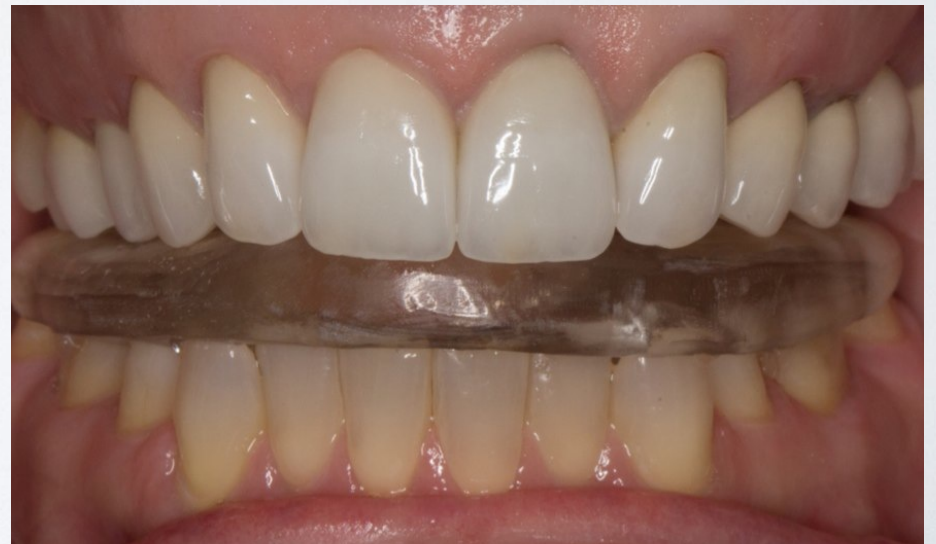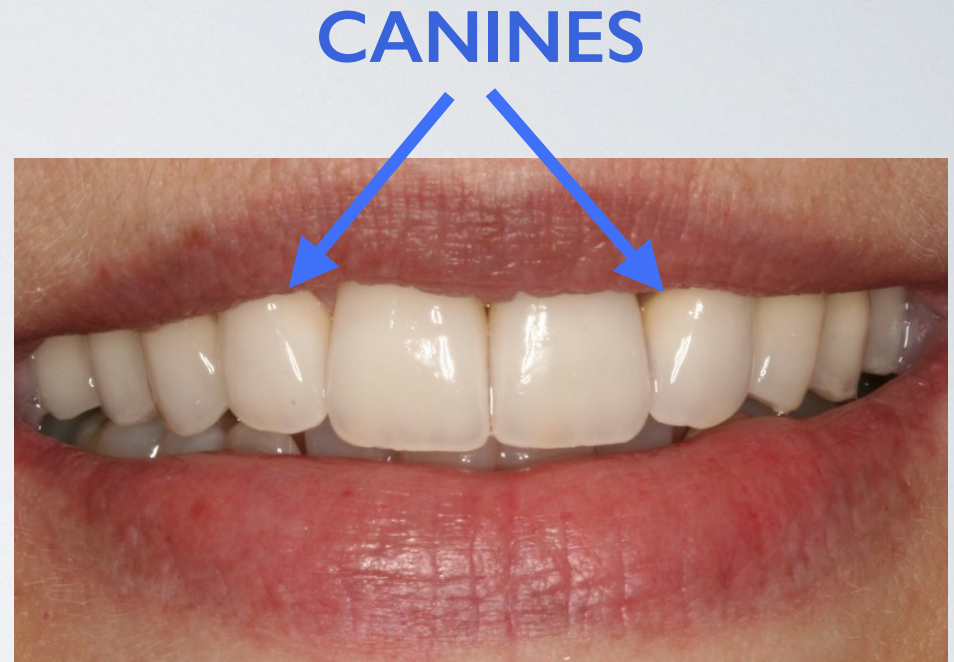
Freedom at splint delivery



By first splint check, patient had reapproximated anterior tooth contact

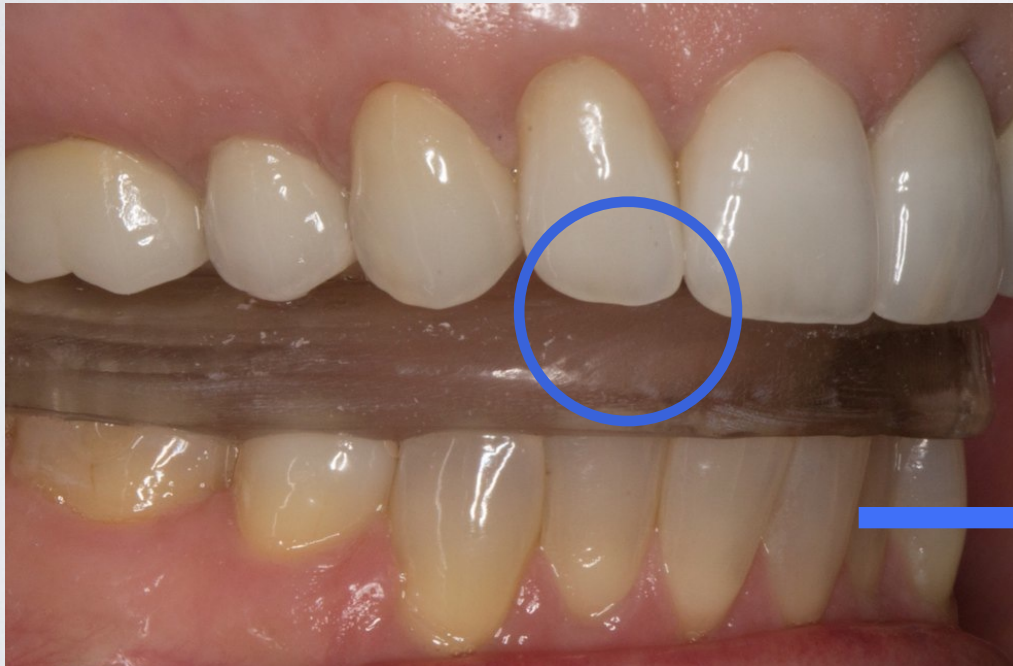CANINE TRANSPOSITION OCCLUSION

Canines in the position of missing lateral incisors, or in the switched position of upper premolars, are rare but can be managed using the same concepts of immediate canine guidance. Regardless of position, the canine itself should be the tooth used for sensing the lateral bite.

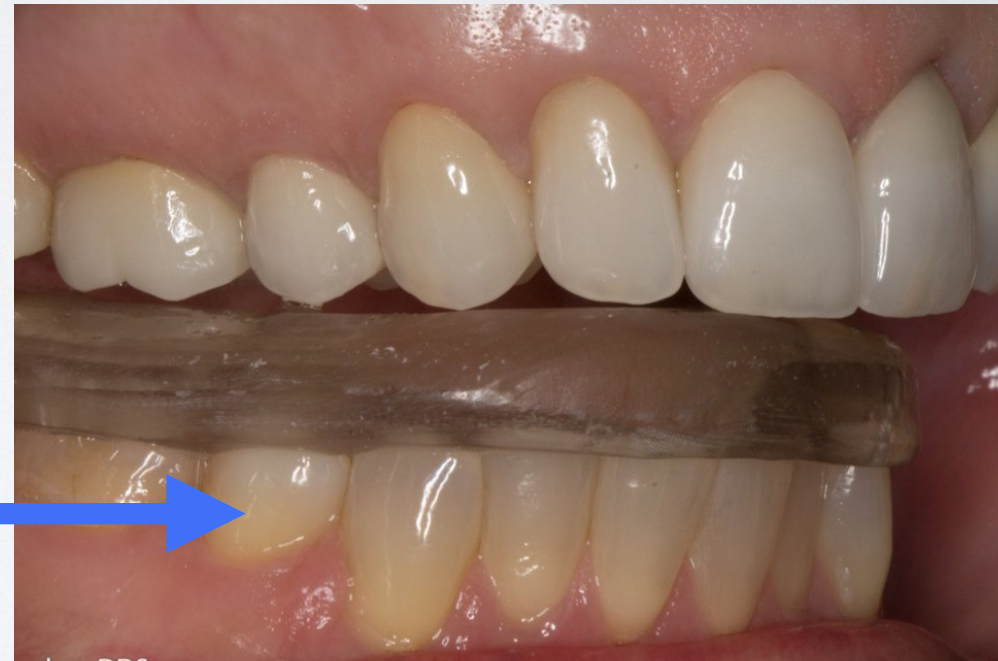

CANINE TRANSPOSITION OCCLUSION

This patient's canine is in the lateral incisor position. The key to this vibration being acceptable is to make it a short, smooth, shallow stroke that is immediately transferred to the central incisor.



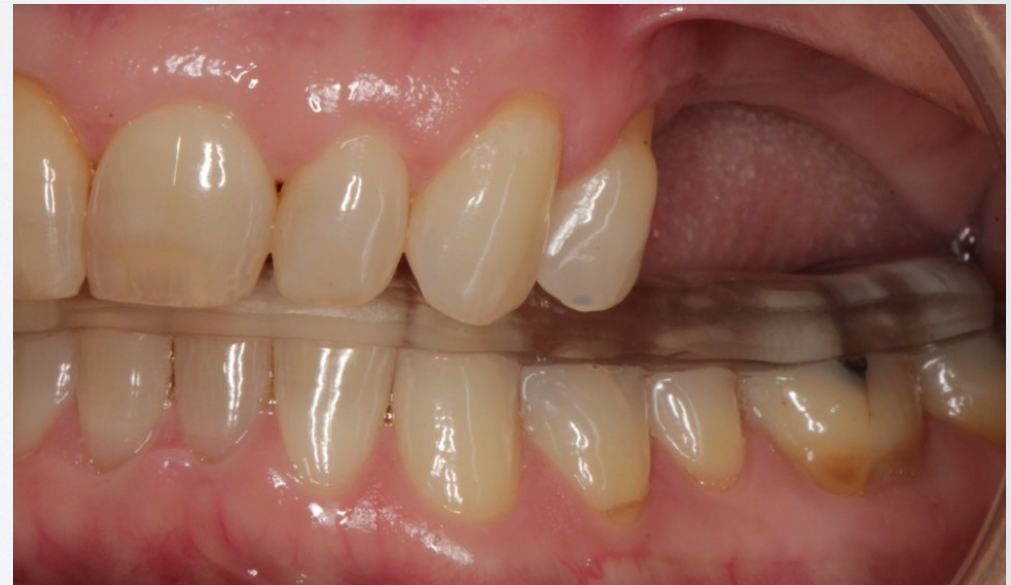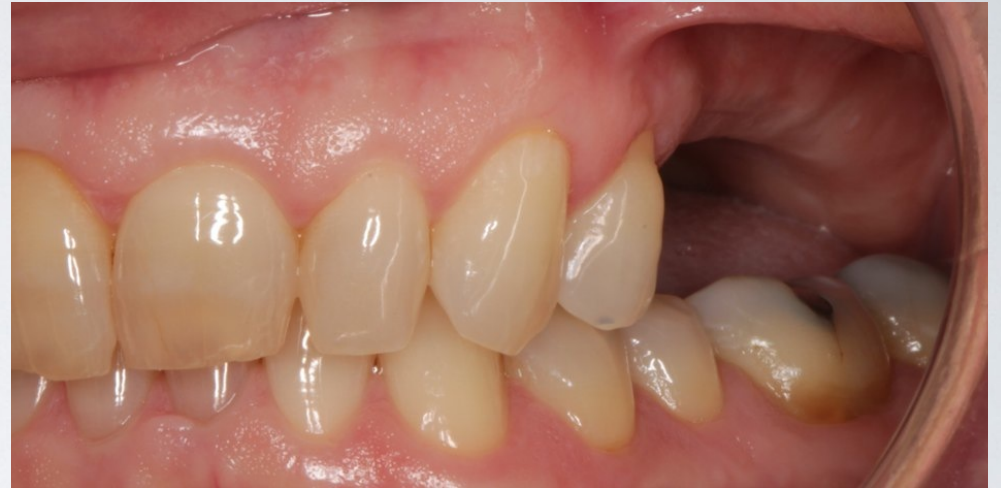**ENGAGING LINGUAL SURFACE OF
TRUE CANINE LIGHTLY**



**RIGHT EXCURSION IS CANINE-GUIDED
WITH QUICK CROSS-OVER to INCISOR**

INCOMPLETE OCCLUSAL SCHEMES

Missing teeth presents a real challenge for allowing the teeth to provide lateral references needed for influencing the sphenoid. When more teeth are missing on the lower than the upper, it is possible to make a lower splint that fills in the missing lower teeth and provides the appropriate reference to the upper teeth. However, when missing upper teeth, it is possible to use a lower splint to create phantom sensation of the missing teeth.



INCOMPLETE OCCLUSAL SCHEMES

For this deep bite case, a lower flat plane splint allows a shallower guidance for all mandibular excursive movements. The upper incisors are exquisitely sensitive to harmonious vibratory input in these movements; hence, the smoothness of these motions will relieve cervical musculature's compensatory need for hypertonicity.

